

## Age-Related Incidence of Aspergillosis in Broiler Chickens in Qalat, Zabul

Hamat Haji Gull<sup>\*1</sup>, Bawer Mohammad Dawood<sup>2</sup>, Noori Gul Nabi<sup>3</sup>, Danish Faisal<sup>4</sup>, Nowbahar Ziaulislam<sup>5</sup>, Takal Hayatullah<sup>6</sup>

<sup>1</sup>Department of Animal Science, Faculty of Agriculture, Zabul Institute of Higher Education, Zabul 4003, Afghanistan; [Hajigullhamat123@gmail.com](mailto:Hajigullhamat123@gmail.com)

<sup>2</sup>Department of Para-Clinic, Faculty of Veterinary Sciences, Afghanistan National Agricultural Sciences and Technology University (ANASTU) 3801, Afghanistan; [Bawerdawood@gmail.com](mailto:Bawerdawood@gmail.com)

<sup>3</sup>Department of Animal Science, Faculty of Agriculture, Zabul Institute of Higher Education, Zabul 4003, Afghanistan; [Gulnabinori66@gmail.com](mailto:Gulnabinori66@gmail.com)

<sup>4</sup>Department of Clinic, Faculty of Veterinary Sciences, Afghanistan National Agricultural Sciences and Technology University, (ANASTU) 3801, Afghanistan; [Faisaldanish443@gmail.com](mailto:Faisaldanish443@gmail.com)

<sup>5</sup>Department of Animal Science, Faculty of Agriculture, Zabul Institute of Higher Education, Zabul 4003, Afghanistan; [Dr.nowbahar21@gmail.com](mailto:Dr.nowbahar21@gmail.com)

<sup>6</sup>Department of Animal Science, Faculty of Agriculture, Zabul Institute of Higher Education, Zabul 4003, Afghanistan; [Hayatullahtakal39@gmail.com](mailto:Hayatullahtakal39@gmail.com)

\*Corresponding author email: [Hajigullhamat123@gmail.com](mailto:Hajigullhamat123@gmail.com)

### ABSTRACT

Aspergillosis is a noncontagious fungal disease affecting birds, primarily caused by *Aspergillus fumigatus*, with *A. flavus* and *A. niger* occurring less frequently. also this disease has a global distribution, thriving in humid environments, while dry litter conditions promote the aerosolization of *Aspergillus* spores. Although *Aspergillus fumigatus* is a ubiquitous and opportunistic fungal pathogen primarily associated with respiratory tract infections, it is also capable of infecting other organs throughout the body. This study, conducted across three commercial broiler chicken farms in Zabul Province, Afghanistan, from January 1, 2024 to June 15, 2024 with a total of 3,000 birds, investigated the incidence of aspergillosis in relation to their age. Using the Slovin's formula, 352 broilers were selected and categorized into three age groups: 1-10 days, 11-20 days, and 21-30 days. The findings indicated that 152 chickens tested positive for aspergillosis, representing an average incidence rate of 43.33%. The incidence varied by age: 61.53% in chickens aged 1–10 days, 40.17% in chickens aged 11–20 days, and 28.20% in chickens aged 21–30 days. Higher infection rates were observed in younger chickens, while older birds showed decreased susceptibility. The significance level for all comparisons was determined at ( $P < 0.05$ ). These findings emphasize the importance of age in the prevalence of Aspergillosis in broiler chickens. The study highlights the need for effective health monitoring and biosecurity measures to control and reduce the incidence of Aspergillosis in poultry farms. And also this research is recommended to explore additional risk factors and to develop targeted prevention and control strategies for Aspergillosis in broiler chickens.

**Keywords:** Aspergillosis, age, broiler chickens, incidence, qalat

### INTRODUCTION

Aspergillosis is recognized as an infectious, yet non-contagious, fungal disease affecting avian species of all ages. The primary causative agent is *Aspergillus fumigatus*, with occasional cases attributed to *A. flavus* and *A. niger*. This disease has a global distribution, thriving in humid environments, while dry litter conditions promote the aerosolization of *Aspergillus* spores

(Barbale, 2002; Flammer, 2002). The genus *Aspergillus* comprises a widely distributed group of fungi, encompassing approximately 200 species (Kunkle *et al.*, 2003). Aspergillosis, a respiratory infection caused by fungi of this genus, is predominantly attributed to *Aspergillus fumigatus*, the most common species responsible for infections. This pathogen is a significant cause of pneumonia in chickens, turkeys, other

avian species, and mammals (Dagenais and Keller, 2009).

Although *Aspergillus fumigatus* is a ubiquitous and opportunistic fungal pathogen primarily associated with respiratory tract infections, it is also capable of infecting other organs throughout the body (Cacciuttolo *et al.*, 2009). Stress is a significant predisposing factor in the development of aspergillosis (Copetti *et al.*, 2004). The inhalation of large quantities of fungal spores is linked to severe fungal infections, which act as a stressor and suppress the immune response, primarily due to the production of toxins such as gliotoxin (Gumussoy *et al.*, 2004; Yokota *et al.*, 2004). Aspergillosis poses a significant challenge in both poultry production and human health. However, due to the difficulty of pre-mortem diagnosis and suboptimal farm management practices, this disease continues to be a persistent issue for farmers (Harold *et al.*, 1997).

The acute form of aspergillosis typically occurs in young chickens, leading to high morbidity and mortality rates. In contrast, the chronic form is characterized by lower morbidity and mortality, predominantly affecting older, weaker birds. Inadequate farm management, in conjunction with a compromised immune system, can exacerbate chronic mortality (Girma *et al.*, 2016). Reports indicate that aspergillosis has a high incidence in birds, particularly during the rainy season. Infected birds that develop untreated respiratory lesions often experience elevated mortality rates, especially in chickens (Abdullahi *et al.*, 1992; Abdu *et al.*, 2002). Aspergillosis is the most prevalent mycotic disease in broilers, with *Aspergillus fumigatus* being the most frequently isolated pathogen (Arné *et al.*, 2011).

This fungus is a common soil saprophyte that thrives on organic matter in warm, humid environments. It has the ability to penetrate the eggshell and infect the developing embryo, leading to classic post-hatch lesions. Several factors contribute to the risk of aspergillosis, including contamination of hatchery equipment by resistant fungal spores, stress, prolonged use of antibiotics or corticosteroids, concurrent

infections, overcrowding, poor nutrition, inadequate hygiene, poor ventilation, and high humidity (Vaezi *et al.*, 2018). The economic impact of aspergillosis on farmers is substantial, primarily because on-farm treatment with topical antifungal drugs is often ineffective. This ineffectiveness not only contributes to high mortality rates but also leads to reduced egg production, poor nutrient conversion, and growth retardation. Additionally, air sacculitis and disseminated granulomata frequently result in the condemnation of carcasses in the poultry meat trade, raising public health concerns (Tohidi *et al.*, 2011). The supplementation of arginine amino acids in broiler chicken diets may enhance immune function, potentially reducing the susceptibility to infections like Aspergillosis, which is influenced by the age and health status of the birds (Danish *et al.*, 2023).

Following infection of the respiratory tract by *Aspergillus*, the fungi can disseminate hematogenously to other organs, leading to the formation of granulomata mediated by lymphocytic and phagocytic reactions. These granulomata, which appear as white to yellowish creamy or caseous nodules of various sizes, contain the organisms and are rarely penetrated by therapeutic drugs (Krishnan *et al.*, 2005). Therefore, the current study aims to evaluate the prevalence of *Aspergillus* in commercial broiler farms through clinical examination and postmortem analysis in Qalat, Zabul Province, Afghanistan.

## MATERIALS AND METHODS

### *Study Area:*

This study was conducted in Zabul Province, Afghanistan, from January 1, 2024, to June 15, 2024, with the objective of mitigating economic losses associated with aspergillosis. Zabul Province is situated near the border of Kandahar Province, approximately 335 km from the capital city, Kabul. The province is located at a latitude of 32.19°N and a longitude of 67.18°E. It has an elevation of approximately 1,743 meters above sea level and experiences an average of 26.8 rainfall days per year. The mean

annual rainfall is 15.67 mm, and the mean annual temperature is 18.29°C (Afghanistan's provinces – zabol at USAID. 2024)

### **Study Animals**

The study was conducted on broiler chickens from three commercial farms, each housing approximately 3,000 chickens. Based on Slovin's formula, ( $n = N / (1+Ne2)$ ), (<https://prudencedcxd.weebly.com>) a total of 352 broilers were selected for the study and categorized into three age-based groups. The first group consisted of 117 chickens aged 1-10 days, the second group included 117 chickens aged 11-20 days, and the third group comprised 117 chickens aged 21-30 days.

### **Study Methodology**

#### **Clinical Examination:**

To ensure biosecurity during sample collection, 117 broilers were randomly selected from a population of 1,000 broilers on each farm, with the farmer's permission. Clinical data were collected based on observable symptoms of aspergillosis, including gasping, stress, diarrhea, nervous signs (e.g., head tilts), eye swelling, paralysis, and respiratory problems.

#### **Post-Mortem Examination:**

Following clinical diagnosis, all broilers identified as positive for aspergillosis were necropsied in a controlled environment, adhering to biosecurity protocols. Post-mortem examinations were conducted to document macroscopic lesions in the trachea, air sacs, stomach, intestines, abdominal cavity, and liver.

#### **Statistical Analysis**


All data were analyzed using SPSS software version 24. One-way ANOVA was employed to compare means across different age groups, with a general confidence interval set at 95%. The significance level for all comparisons was determined at ( $P<0.05$ ).

## **RESULTS**

### **Ante-Mortem findings**

The clinical examination of 117 broilers from each of the three age groups revealed a range of

symptoms consistent with aspergillosis. The observed symptoms included gasping, stress, diarrhea, nervous signs (such as head tilts), eye swelling, paralysis, and respiratory problems (Figure 1).



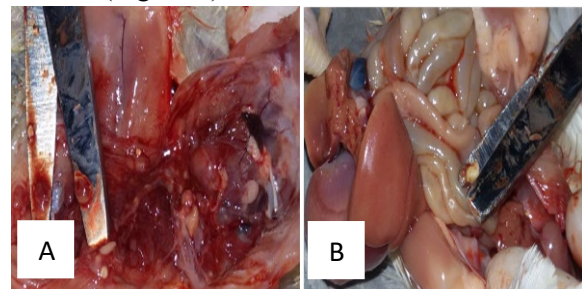
**Figure 1.** Clinical Signs of Aspergillosis in Broilers.

**A.** Nervous signs including head tilts, restlessness, loss of appetite, and gray skin.

**B.** Severe symptoms such as paralysis, intense gasping, dyspnea, eye swelling, and respiratory problems.

#### **Post-Mortem Findings:**

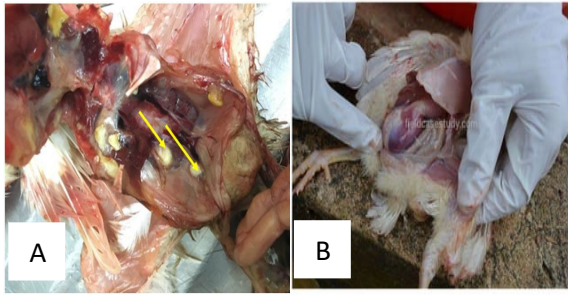
All chickens that tested positive for aspergillosis based on clinical signs were necropsied in a controlled environment, adhering to biosecurity protocols. The examination revealed cheese-shaped exudate nodules in the air sacs and trachea. Additionally, whitish nodular lesions were observed on the heart, gizzard, and liver. The respiratory system also showed gray, multiple nodular granulomatous lesions in the lungs, as well as nodules in the skin and breast muscle (Figure 2).



**Figure 2.** Macroscopic Lesions Observed in Aspergillosis.

**A.** Whitish caseous nodular lesions on the heart, gizzard, and liver.

**B.** Whitish caseous nodular lesions on the intestine.



**Figure 3.** Caseous Lesions in Aspergillosis.

**A.** White-yellowish caseous nodules and cheesy exudate on the outer surface of the, proventriculus and liver.

**B.** White-yellowish caseous nodules and cheesy exudate in the proventriculus and thoracic cavity.

Statistical analysis using SPSS software version 24, employing one-way ANOVA, indicated significant differences in the prevalence and severity of lesions among the age groups ( $P < 0.05$ ). The results suggest that the incidence and severity of aspergillosis-related symptoms and lesions vary significantly with age (Table 1). A total of 352 chickens were included in this study, of which 152 cases were positive for Aspergillosis, resulting in an overall prevalence of 43.33%. Age-specific analysis revealed that in farms with chickens aged 1-10 days, 72 out of 117 birds were positive, corresponding to an incidence rate of 61.53%. In farms where chickens were 11-20 days old, 47 out of 117 birds tested positive, with an incidence rate of 40.17%. Similarly, in farms with chickens aged 21-30 days, 33 out of 117 birds were positive, resulting in an incidence rate of 28.20%.

**Table 1:** Age-wise Prevalence of Aspergillosis in Broiler Chickens.

| Age (days)   | Total No. of Birds observed | Infected Birds | Prevalence (%) $\pm$ SE        |
|--------------|-----------------------------|----------------|--------------------------------|
| 1-10         | 117                         | 72             | 61.53 $\pm$ 0.045 <sup>a</sup> |
| 11-20        | 117                         | 47             | 40.17 $\pm$ 0.045 <sup>b</sup> |
| 21-30        | 117                         | 33             | 28.20 $\pm$ 0.042 <sup>c</sup> |
| <b>Total</b> | 352                         | 152            | 43.33 $\pm$ 0.026              |

Values with different superscripts (a, b, c) indicate significant differences in prevalence between age groups at the 0.05 level.

## DISCUSSION

The present study evaluated the incidence of aspergillosis in broiler chickens based on their age. The overall incidence rate was found to be 43.33%, with a total of 152 positive cases. Among chickens aged 1–10 days, 72 out of 117 birds were infected, yielding a prevalence of 61.53%. In chickens aged 11–20 days, 47 out of 117 birds tested positive, resulting in a prevalence of 40.17%. Meanwhile, in chickens aged 21–30 days, 33 out of 117 birds were positive, corresponding to a prevalence rate of 28.20%. The findings suggest that younger chickens had a higher incidence of Aspergillosis compared to older chickens. This may be attributed to the increased susceptibility of younger chickens.

Sultana and colleagues conducted research in 2013 on 20-30 day-old chickens. A total of 900 chickens were studied, out of which 220 tested positive, resulting in an incidence rate of 24.45% (Sultana et al., 2015). Similarly, in our study, 21-30 day-old chickens were examined, and 117 were found to be positive, yielding an incidence rate of 28.20%.

In 2016, Vahsen and colleagues studied 35-45 day-old chickens. They examined 1,200 chickens, of which 190 tested positive, leading to an incidence rate of 32.5% (Vahsen et al., 2021). Based on the incidence rate, our research aligns closely with Vahsen's findings. In our study, 117 chickens aged 21-30 days were positive, with an incidence rate of 28.20%. The observed similarity could be due to effective farm or food management practices.

A study conducted in India in 2016 focused on 10-25 day-old chickens. A total of 2,000 chickens were studied, with 710 testing positive, giving an incidence rate of 35.3% (Uddin et al., 2010). Similarly, in our research, 47 chickens aged 1-10 days tested positive, with an incidence rate of 40.17%.

Research conducted in Bangladesh at Haji Mohammad Danish University of Science and

Technology during 2022-2023 studied 1-15 day old chickens. Among the 394 chickens examined, 170 were positive, with an incidence rate of 43.14% (Arafat et al., 2021). In contrast, our research showed a higher incidence rate of 61.53%, with 72 out of 117 chickens aged 1-10 days testing positive. This discrepancy suggests that proper management practices are needed to maintain farm health.

In 2017, a study in Dubok City focused on 42-30 day-old chickens from two commercial farms. Out of 16,800 chickens studied, 15,009 were positive, resulting in an incidence rate of 89.51% (Ahamad et al., 2018). In contrast, our research showed an incidence rate of 61.53%, with 117 chickens aged 21-30 days testing positive. The disparity may be attributed to overcrowding or improper air circulation management in the farms.

Overall, our study demonstrates a significant association between the age of chickens and the incidence of Aspergillosis. The findings emphasize the importance of age-based health monitoring and the implementation of effective biosecurity measures to mitigate the risk of Aspergillosis in poultry farms. Also future research should include to investigate the impact of environmental and management practices on the prevalence of Aspergillosis and disease management strategies, including improved environmental management are essential. Additionally, educational programs for

farmers on early detection and effective treatment are recommended.

## CONCLUSION

This study demonstrates that the prevalence of Aspergillosis in broiler chickens is significantly influenced by the age of the chickens. The incidence was highest among younger chickens, particularly those aged 1–10 days. These findings suggest that younger chickens may contribute to a higher risk of Aspergillosis outbreaks. Effective management practices, including enhanced biosecurity measures, are crucial to reducing the incidence of Aspergillosis in poultry farms. Further research is recommended to explore additional risk factors and to develop targeted prevention and control strategies for Aspergillosis in broiler chickens.

**CONFLICT OF INTEREST:** All authors express no conflict of interest in any part of the research.

**FUNDING:** This research received no external funding.

**AUTHORS CONTRIBUTIONS:** H-H was responsible for the research design, data collection, and drafting of the manuscript. F-D and M-B provided supervision, critical revision, and academic refinement of the manuscript. The other authors contributed with minor revisions.

---

## REFERENCES

- Abdullahi, S. U., Abdu, P. A., Ibrahim, M. A., George, B. D. J., Saidu, L., & Adekeye, J. O. (1992). Incidence of diseases of poultry caused by nonviral infectious agents in Zaria, Nigeria. World Poultry Congress, Amsterdam, The Netherlands, 20-24 September, 8 (6)1, 159.
- Arné, P., Thierry, S., Wang, D., Deville, M., Le Loc'h, G., Desoutter, A., Femenia, F., Nieguitsila, A., Huang, W., Chermette, R., & Guillot, J. (2011). *Aspergillus fumigatus* in poultry. International Journal of Microbiology, 10 (13), 1-14.
- Akan, M., Haziroğlu, R., İlhan, Z., Sareyyüpoğlu, B., & Tunca, R. (2002). A case of aspergillosis in a broiler breeder flock. Avian Disease, 46(8), 497-501.

- Abdu, P. A., Saidu, L., & George, B. D. J. (2002). Diseases of local poultry in Nigeria. *Discovery Innovation*, 76(4), 1-2.
- Afghanistan's Provinces – Zabul at USAID. (n.d.). Usaid.Gov. Retrieved December 9, 2024, from <http://afghanistan.usaid.gov/en/Province.34.aspx>.
- Arafat, M.Y., Islam, M.M., Ahamed, S., Mahmud, M.M., Rahman, M.B., Nazir, K.N.H., 2021. Molecular detection of *Aspergilla* from commercial chicken selected areas of Bangladesh. *J. Adv. Vet. Anim. Res.* 9(2), 184.
- Ahamad, D.B., Ranganathan, V., Punniyamurthy, N., Sivaseelan, S., Puvarajan, B., 2018. Pathology of systemic aspergillosis in a desi chicken. *Shanlax Int. J. Vet. Sci.* 5(4), 36-42.
- Barbale, L. O. (2002). Bacterial and mycotic diseases of companion birds. In *Proceedings of the North American Veterinary Conference, Small Animal Edition 16 (2)*, 874-875.
- Bernaert, L. A., Pasmans, F., Van Waeyenberghe, L., & Haesebrouck, F. (2010). *Aspergillus* infections in birds: A review. *Avian Pathology*, 39 (5), 325-331.
- Bernaert, L. A., Pasmans, L. A., Van Waeyenberghe, F. L., Haesebrouck, F., & Martel, A. (2010). *Aspergillus* infections in birds: A review. *Avian Pathology*, 39(5), 325-333.
- Copetti, M. V., Segabinazi, S. D., Flores, M. L., Alves, S. H., & Santurio, J. M. (2004). Pulmonary aspergillosis outbreak in *Rhea americana* in Southern Brazil. *Mycopathologia*, 15(7), 269-271.
- Cacciutolo, E., Rossi, G., Nardoni, S., Legrottaglie, R., & Mani, P. (2009). Anatomopathological aspects of avian aspergillosis. *Veterinary Research Communications*, 33(1), 521-527.
- Danish, F., Amarkhil, R., Adil, N. J., Azizi, M. N., & Hematzai, N. (2023). Dietary Arginine as a Growth Promoter for Broiler Chickens. *Nangarhar University International Journal of Biosciences*, 2(03), 80-86.
- David, S. (2000). Aspergillosis. In *Poultry Health and Management* (4th ed., pp. 35-46). ELST Oxford: Blackwell Scientific Publications. 14(7) 220 – 230.
- Dhama, K., Chakraborty, R., Verma, A. K., Tiwari, R., Barathidasan, R., Kumar, A., & Singh, D., S. (2013). Fungal/mycotic diseases of poultry – Diagnosis, treatment and control: A review. *Pakistan Journal of Biological Sciences*, 16(23), 1626-1640.
- Flammer, K. (2002). Diagnosis and management of avian aspergillosis. In *Proceedings of the North American Veterinary Conference, Small Animal Edition 3(4)*, 848-850.
- Femenia, F., Fontaine, J. J., Fulleringer, S. L., Berkova, N., Huet, D., Towanou, N., Rakotovao, F., Granet, O. I., Le Loc'h, G., Arné, P., & Guillot, J. (2007). Clinical, mycological and pathological findings in turkeys experimentally infected by *Aspergillus fumigatus*. *Avian Pathology*, 36 (3), 213-219.
- Gümüşsoy, K. S., Uyanik, F., Atasever, A., & Cam, Y. (2004). Experimental *Aspergillus fumigatus* infection in quails and results of treatment with itraconazole. *Journal of Veterinary Medicine*, 51(1), 34-38.
- Girma, G., Abebaw, M., Zemene, M., Mamuye, Y., & Getaneh, G. (2016). A review on aspergillosis in poultry. *Journal of Veterinary Science & Technology*, 7(6), 382.
- Harold, L. C., & John, L. R. (1997). Fungal infections. In B. W. Calnek, B. H. John, W. B. Charles, R. M. Larry, & Y. M. Saif (Eds.), *Diseases of poultry* (10th ed., pp. 359-388). Iowa State University Press.
- Kunkle, R. A. (2003). Aspergillosis. In Y. M. Saif, H. J. Barnes, J. R. Glisson, et al. (Eds.), *Diseases of poultry* (pp. 823-895). Iowa State University Press.
- Krishnan, S., Manavathu, E. K., & Chandrasekar, P. H. (2005). A comparative study of fungicidal activities of voriconazole and amphotericin B against hyphae of *Aspergillus fumigatus*.

- Journal of Antimicrobial Chemotherapy, 55 (7), 914-920.
- Lobna, M. A., Abdel, S., & Ali, F. (2014). Epidemiological study of aspergillosis in chickens and human contacts in chicken farms at Kalyoubia Governorate. *Journal of Agriculture and Veterinary Science*, 7 (7), 20-24.
- Martin, M. P., Bouck, K. P., Helm, J., Dykstra, M. J., Wages, D. P., & Barnes, H. J. (2007). Disseminated *Aspergillus flavus* infection in broiler breeder pullets. *Avian Diseases*, 51(2), 626-631.
- Nardoni, S., Ceccherelli, R., Rossi, M., & Mancianti, F. (2006). Aspergillosis in *Larus cachinnans* micaellis: Survey of eight cases. *Mycopathologia*, 16(1), 317-321.
- Research Assignments - Slovin's Formula. (n.d.). Retrieved December 9, 2024, from <https://prudencexd.weebly.com>.
- Saleh, A. A., Hayashi, K., Ijiri, D., & Ohtsuka, A. (2014). Beneficial effects of *Aspergillus awamori* in broiler nutrition. *World's Poultry Science Journal*, 70(4), 857-864.
- Sultana, S., Rashid, S.M.H., Islam, M.N., Ali, M.H., Islam, M.M., Azam, M.G., 2015. Pathological investigation of avian aspergillosis in commercial broiler chicken at Chittagong district. *Int. J. Innov. Appl. Stud.* 10(1), 366.
- Souza, M. J., & Degernes, L. A. (2005). Prevalence of aspergillosis and distribution of lesions in wild swans in Northwest Washington State, 2000-2002. *Journal of Avian Medicine and Surgery*, 19(2), 98-106.
- Tomee, J. F., & Kauffman, H. F. (2000). Putative virulence factors of *Aspergillus fumigatus*. *Journal of the British Society for Allergy and Clinical Immunology*, 30 (4), 476-484.
- Tohidi, M., Najafzadeh, M. J., Alizadeh, M., & Seyedmousavi, S. (2018). Predominance of non-fumigatus *Aspergillus* species among patients suspected to pulmonary aspergillosis in a tropical and subtropical region of the Middle East. *Microbial Pathogenesis*, 11(6), 296-300.
- Uddin, M.B., Ahmed, S.S.U., Hassan, M.M., Khan, S.A., Mamun, M.A., 2010. Prevalence of poultry diseases at Narsingdi, Bangladesh. *Int. J. Biol. Res.* 1(6), 9-13.
- Vashen, T., Zapata, L., Guabiraba, R., Melloul, E., Cordonnier, N., Botterel, F., Guillot, J., Arné, P., Risco-Castillo, V., 2021. Cellular and molecular insights on the regulation of innate immune responses to experimental aspergillosis in chicken and turkey poults. *Med. Mycol.* 59(5), 465-475.
- Vaezi, A., Fakhim, H., Arastehfar, A., Shokohi, T., Hedayati, M. T., Khodavaisy, S., Rezaei, M., Matehkolaei, A., Badiee, P., Hagen, F., Lass-Flörl, C., Dannaoui, E., Meis, J. F., & Badali, H. (2018). In vitro antifungal activity of amphotericin B and 11 comparators against *Aspergillus terreus* species complex. *Mycoses*, 61(5), 134-142.
- Yokota, T., Shibahara, T., Wada, Y., Hirak, I. R., Ishikawa, Y., & Kadota, K. (2004). *Aspergillus fumigatus* infection in an ostrich (*Struthio camelus*). *\*Journal of Veterinary Medical*.